

The Full File have 1-9 Pages : Pig Dissection Exercises


Laboratory Manual for Anatomy and Physiology, 6e (Wood)

Pig Dissection Exercises

Pig Dissection Exercise 1: Pig Muscular System

Pig Dissection Exercise 1: Pre-Lab Questions

1) Which term refers to the ventral surface of a four-legged animal?



- A) inferior
- B) superior
- C) caudal
- D) cephalic

Answer: A

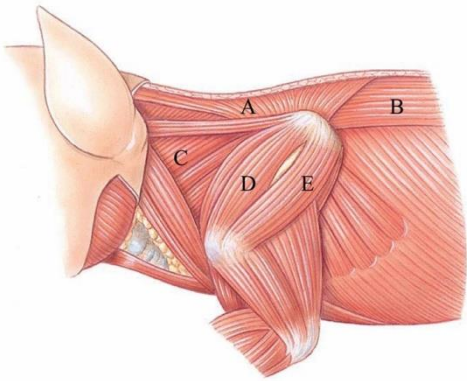
Explanation:

B) Anatomical position for a four-legged animal is all four limbs on the ground. Superior refers to the back (dorsal) surface.

C) Anatomical position for a four-legged animal is all four limbs on the ground. Caudal refers to posterior structures, or those towards the tail.

D) Anatomical position for a four-legged animal is all four limbs on the ground. Cephalic refers to being towards the front or anterior region of the animal.

2) Identify the longissimus dorsi in the following figure.



- A) A
- B) B
- C) C
- D) D
- E) E

Answer: B

Explanation:

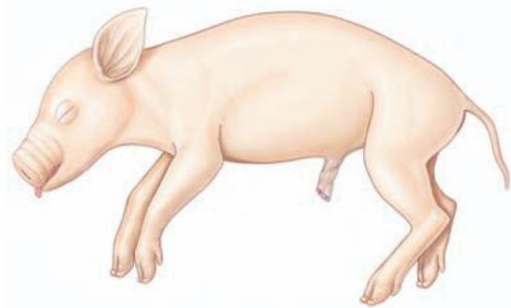
A) Letter "A" is marking the rhomboideus cervicis.

C) Letter "C" is marking the splenius.

D) Letter "D" is marking the infraspinatus.

E) Letter "E" is marking the supraspinatus.

3) Which term refers to the tail end of a four-legged animal?



- A) caudal
- B) superior
- C) inferior
- D) cephalic

Answer: A

Explanation:

B) The term superior refers to the back (dorsal) surface of a four-legged animal.

C) The term inferior refers to the ventral surface of a four-legged animal.

D) The term cephalic (anterior) refers to being toward the front or anterior region of the animal.

4) Which group of muscles covers the dorsal surface of the neck and scapula?

- A) pectoralis group
- B) deltoid group
- C) rhomboideus group
- D) trapezius group

Answer: D

Explanation:

- A) The pectoralis group consists of the large muscles covering the ventral surface of the chest.
- B) The deltoid group comprises the shoulder muscles lateral to the trapezius group.
- C) The rhomboideus group connects the spinous processes of cervical and thoracic vertebrae with the vertebral border of the scapula.

5) Which group of muscles covers the ventral surface of the chest?

- A) trapezius group
- B) deltoid group
- C) rhomboideus group
- D) pectoralis group

Answer: D

Explanation:

- A) The trapezius group consists of the muscles covering the dorsal surface of the neck and scapula.
- B) The deltoid group comprises the shoulder muscles lateral to the trapezius group.
- C) The rhomboideus group connects the spinous processes of cervical and thoracic vertebrae with the vertebral border of the scapula.

Pig Dissection Exercise 1: Post-Lab Questions

1) Which statement regarding the storage of your pig is the most correct?

- A) The pig should be dried and then stored in a sealed bag.
- B) The pig should be stored in a sealed bag covered in distilled water.
- C) The pig should be stored in a sealed bag with exposed muscles covered with paper towels that have been dampened with fixative.
- D) The pig should be stored on the dissecting pan without any coverings.

Answer: C

Explanation:

- A) Always remoisten the body, skin, and other wrappings with fixative prior to storage and then place the pig in a sealed bag.
- B) Never rinse the pig with water. Doing so will remove the preservative and promote the growth of mold. Always remoisten the body, skin, and other wrappings with fixative prior to storage.
- D) Always remoisten the body, skin, and other wrappings with fixative prior to storage and then place the pig in a sealed bag.

2) To begin dissecting the pig, place it _____ side down on the dissecting tray.

- A) ventral
- B) caudal
- C) cephalic
- D) dorsal

Answer: D

Explanation:

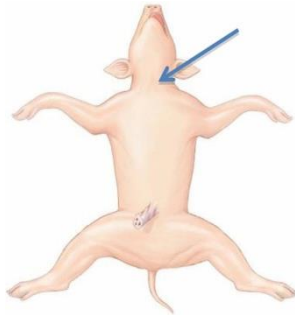
- A) The first incision will be made superficially into the ventral (abdominal) surface. Thus, the pig should be lying with its dorsal side down.
- B) Caudal refers to the tail end of the pig. The first incision will be made superficially into the ventral surface. Thus, the pig should be lying with its dorsal side down.
- C) Cephalic refers to the anterior end of the pig. The first incision will be made superficially into the ventral surface. Thus, the pig should be lying with its dorsal side down.

- 3) Where should the first incision be made when dissecting a pig?
- A) on the lateral side of the ventral surface near the umbilical cord
 - B) on the midline of the ventral surface at the base of the neck
 - C) on the lateral side of the dorsal surface near the neck
 - D) on the midline of the dorsal surface just anterior to the tail

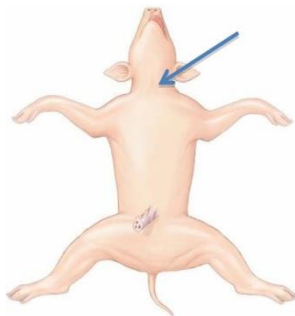
Answer: B

Explanation:

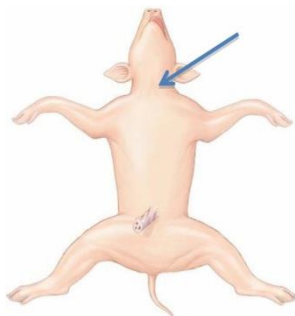
A) The first incision should be a short and shallow incision on the midline of the ventral surface at the base of the neck.



C) The first incision should be a short and shallow incision on the midline of the ventral surface at the base of the neck.



D) The first incision should be a short and shallow incision on the midline of the ventral surface at the base of the neck.



4) How should the skin be separated from the underlying fascia?

A) use your fingers or a blunt probe to separate the skin from the underlying muscle and connective tissues

B) use the scalpel to separate the skin from the underlying muscle and connective tissues

C) use the pointed end of a pair of scissors to separate the skin from the underlying muscle and connective tissues

Answer: A

Explanation:

B) To remove the skin from the underlying fascia, you should not use sharp tools as this may cut or damage the muscles.

C) To remove the skin from the underlying fascia, you should not use sharp tools as this may cut or damage the muscles.

5) In pigs, the trapezius group of muscles is composed of three distinct muscles. How many muscle(s) make up the trapezius in humans?

A) three

B) two

C) one

D) four

Answer: C

Explanation:

A) The trapezius group of muscles covers the dorsal surface of the neck and the scapula. The single trapezius in humans occurs as three distinct muscles in pigs.

B) The trapezius group of muscles covers the dorsal surface of the neck and the scapula. The single trapezius in humans occurs as three distinct muscles in pigs.

D) The trapezius group of muscles covers the dorsal surface of the neck and the scapula. The single trapezius in humans occurs as three distinct muscles in pigs.

6) Which of the following is a large, flat muscle that lies posterior to the trapezius group?

A) latissimus dorsi

B) sternohyoid

C) deltoid

D) supraspinatus

Answer: A

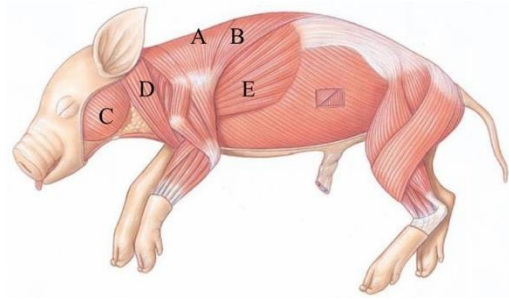
Explanation:

B) The sternohyoid is a flat, strap-like muscle that lies on the ventral side of the neck.

C) The deltoid is a thin muscle of the shoulder that lies lateral to the trapezius group.

D) The supraspinatus lies deep to the acromiotrapezius and occupies the lateral surface of the scapula in the supraspinous fossa.

7) Identify the spinotrapezius in the following figure.



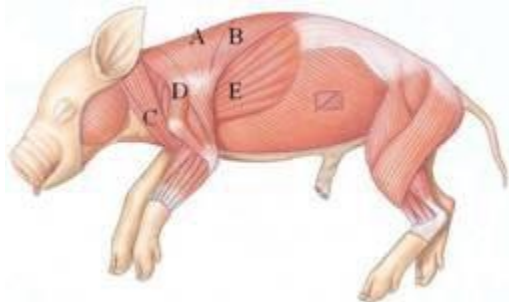
- A) A
- B) B
- C) C
- D) D
- E) E

Answer: B

Explanation:

- A) Letter "A" is marking the acromiotrapezius.
- C) Letter "C" is marking the masseter.
- D) Letter "D" is marking the brachiocephalic.
- E) Letter "E" is marking the latissimus dorsi.

8) Identify the brachiocephalic in the following figure.



- A) A
- B) B
- C) C
- D) D
- E) E

Answer: C

Explanation:

- A) Letter "A" is marking the acromiotrapezius.
- B) Letter "B" is marking the spinotrapezius.
- D) Letter "D" is marking the deltoid.
- E) Letter "E" is marking the latissimus dorsi.

9) Which muscle is located at the axillary border of the scapula where it originates?

- A) splenius
- B) supraspinatus
- C) infraspinatus
- D) rhomboideus thoracis
- E) teres major

Answer: E

Explanation:

A) The splenius is a broad, flat, thin muscle that covers most of the lateral surface of the cervical and thoracic vertebrae. It is deep to the rhomboideus capitus.

B) The supraspinatus occupies the lateral surface of the scapula in the supraspinous fossa.

C) The infraspinatus occupies the infraspinous fossa on the lateral surface of the scapula.

D) The rhomboideus thoracis is a fan-shaped muscle and is the most posterior muscle of the rhomboideus group.

10) Which muscle is a broad, flat, thin muscle that covers most of the lateral surface of the cervical and thoracic vertebrae?

- A) splenius
- B) supraspinatus
- C) infraspinatus
- D) rhomboideus thoracis
- E) teres major

Answer: A

Explanation:

B) The supraspinatus occupies the lateral surface of the scapula in the supraspinous fossa.

C) The infraspinatus occupies the infraspinous fossa on the lateral surface of the scapula.

D) The rhomboideus thoracis is a fan-shaped muscle and is the most posterior muscle of the rhomboideus group.

E) The teres major is located at the axillary border of the scapula.

11) Which group of muscles connects the spinous processes of cervical and thoracic vertebrae with the vertebral border of the scapula?

- A) trapezius group
- B) rhomboideus group
- C) intercostal group
- D) pectoralis group

Answer: B

Explanation:

A) The trapezius group of muscles covers the dorsal surface of the neck and the scapula.

C) The intercostal group consists of two layers of muscles between the ribs that move the ribs during respiration.

D) The pectoralis group consists of the large muscles covering the ventral surface of the chest.

