

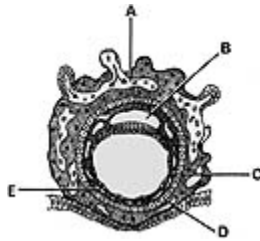
Moore: Before we are Born, 8th Edition

Chapter 02: Formation of Bilaminar Embryonic Disc and Chorionic Sac

Test Bank

MULTIPLE CHOICE

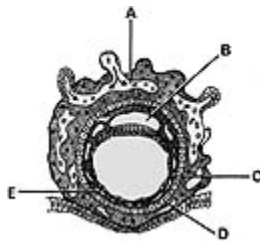
Directions: Each group of questions below consists of a numbered list of descriptive words or phrases accompanied by a diagram with certain parts indicated by letters or by a list of lettered headings. For each numbered word or phrase, select the lettered part or heading that matches it correctly and then insert the letter in the space to the right of the appropriate number. Sometimes more than one numbered word or phrase may be correctly matched to the same lettered part or heading.



1. _____ Extraembryonic coelom
- a. A
 - b. B
 - c. C
 - d. D
 - e. E

ANS: E

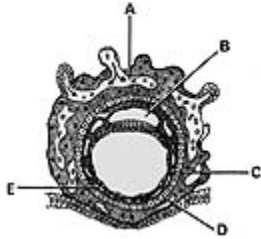
The extraembryonic coelom, part of which is indicated in the diagram, consists of isolated spaces in the extraembryonic mesoderm. Later, these spaces coalesce to form a single, large cavity.



2. _____ Cytotrophoblast
- a. A
 - b. B
 - c. C
 - d. D
 - e. E

ANS: D

The cytotrophoblast is the inner layer of the trophoblast. It gives rise to (1) the outer layer of trophoblast (syncytiotrophoblast), (2) amnioblasts (cells that form the amnion), and (3) part of the extraembryonic mesoderm. The cytotrophoblast, as the prefix cyto- implies, is a cellular layer.



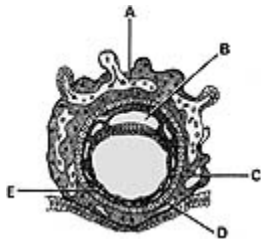
3.

_____ Lacunar network

- a. A
- b. B
- c. C
- d. D
- e. E

ANS: A

The lacunar networks form by coalescence of lacunae in the syncytiotrophoblast. As the maternal sinusoids are eroded, blood seeps into these networks. Nutrients in the embryotroph diffuse through the two layers of trophoblast and pass to the embryo by way of the extraembryonic coelom.



4.

_____ Epiblast forms its floor

- a. A
- b. B
- c. C
- d. D
- e. E

ANS: B

The floor of the amniotic cavity is formed by the epiblast. The amnion enclosing the amniotic cavity is attached to the epiblast of the embryonic disc. Initially, some amniotic fluid may be secreted by the amniotic cells, but most of it is derived from the maternal blood.

5. _____ Develops as a localized thickening of hypoblast

- a. Corpus luteum

- b. Zona pellucida
- c. Prechordal plate
- d. Ectopic implantation
- e. Chorionic sac

ANS: C

The prechordal plate indicates the future cranial end of the embryo and the future site of the mouth. It is a circular area of endoderm that is firmly adherent to the overlying embryonic epiblast. It is an important landmark in the early embryo and serves as an organizer of the cranial region of the embryo.

6. _____ Develops from a ruptured ovarian follicle
- a. Corpus luteum
 - b. Zona pellucida
 - c. Prechordal plate
 - d. Ectopic implantation
 - e. Chorionic sac

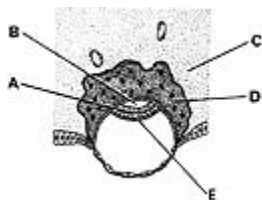
ANS: A

The corpus luteum develops from the ovarian follicle after ovulation. Under the influence of luteinizing hormone (LH) produced by the adenohypophysis (anterior lobe of pituitary gland), the ruptured follicle develops into a glandular structure. At ovulation, the walls of the follicle collapse and, with cells of the theca folliculi, form the corpus luteum. The corpus luteum is an important source of progesterone for about 4 months. After this, the placenta is the major producer of this hormone.

7. _____ Surrounds embryo, amnion, and umbilical vesicle (yolk sac)
- a. Corpus luteum
 - b. Zona pellucida
 - c. Prechordal plate
 - d. Ectopic implantation
 - e. Chorionic sac

ANS: E

The chorion forms the chorionic sac from the wall of which the embryo, its amnion and umbilical vesicle are suspended by the connecting stalk. The chorionic sac gives rise to the embryonic part of the placenta.

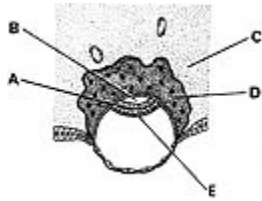


8. _____ Derived from cytotrophoblast
- a. A
 - b. B
 - c. C

- d. D
- e. E

ANS: D

The syncytiotrophoblast, a multinucleated protoplasmic mass, is derived from the cytotrophoblast. Cells of the cytotrophoblast divide mitotically, and some of these cells move outward, where they fuse with and become part of the increasing mass of syncytiotrophoblast. The syncytiotrophoblast produces human chorionic gonadotropin, which acts like luteinizing hormone in maintaining the corpus luteum. Later, it also produces other hormones. The syncytiotrophoblast is actively involved in implantation.

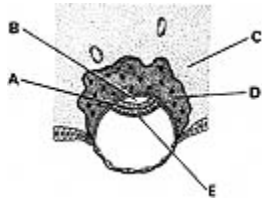


9. _____ Ventral layer of embryonic disc

- a. A
- b. B
- c. C
- d. D
- e. E

ANS: E

The hypoblast (primordial endoderm) forms the ventral layer of the embryonic disc. It is first recognizable on the ventral surface of the embryoblast about 7 days after fertilization.

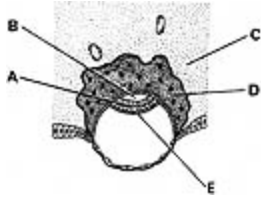


10. _____ Site of the decidual reaction

- a. A
- b. B
- c. C
- d. D
- e. E

ANS: C

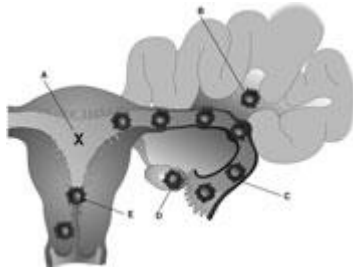
The connective tissue in the compact layer of the endometrium in the region of the implanting blastocyst is the site of cellular and other changes known as the decidual reaction. The enlarged decidual cells contain large amounts of glycogen and lipids that provide nourishment for the embryo.



11. _____ Lies between the cytotrophoblast and the epiblast
- a. A
 - b. B
 - c. C
 - d. D
 - e. E

ANS: B

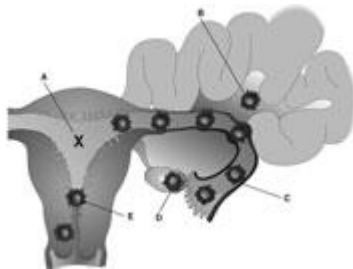
The amniotic cavity lies between the cytotrophoblast and the epiblast of the embryonic disc. Cells from the epiblast (amnioblasts) soon form a thin roof over this cavity called the *amnion*. It is continuous with the epiblast of the embryonic disc.



12. _____ Most common site of an ectopic pregnancy
- a. A
 - b. B
 - c. C
 - d. D
 - e. E

ANS: C

The most common site of an ectopic pregnancy is the uterine tube, usually in the ampulla or isthmus. The incidence of tubal pregnancy ranges from 1 in 80 to 1 in 250 pregnancies, depending on the geographic location, socioeconomic level, and age of the pregnant woman. Pelvic inflammatory disease is a common cause of tubal ectopic pregnancy. As the embryo increases in size, the uterine tube ruptures, leading to hemorrhage and a serious threat to the mother's life.



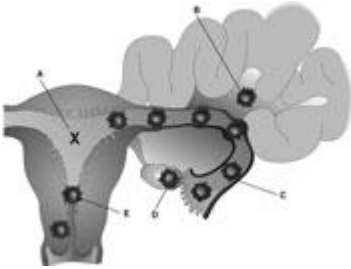
- 13.

_____ Abdominal pregnancy

- a. A
- b. B
- c. C
- d. D
- e. E

ANS: B

In an abdominal pregnancy, the conceptus develops on the peritoneal surfaces of the abdominal cavity. Abdominal pregnancies are relatively uncommon (about 0.03% of all ectopic pregnancies), and they are usually associated with intra-abdominal hemorrhage and severe abdominal pain. Rarely, the embryo continues to develop until term and a live fetus may be delivered surgically. In some cases, the abdominal fetus dies and becomes calcified, forming a so-called *stone fetus* or *lithopedion*.



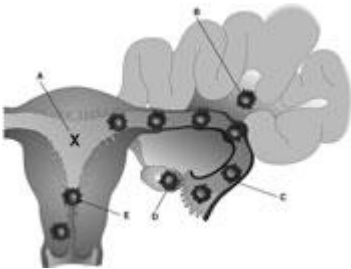
14.

_____ Usual site of implantation

- a. A
- b. B
- c. C
- d. D
- e. E

ANS: A

The blastocyst usually implants on the superior part of the posterior wall of the uterine cavity. Implantation occurs slightly more often on the posterior than on the anterior wall.



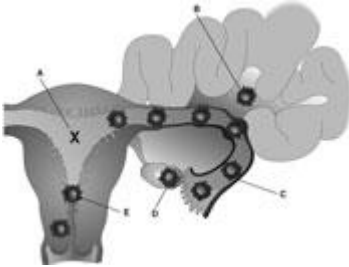
15.

_____ Implantation at internal os

- a. A
- b. B
- c. C
- d. D
- e. E

ANS: A

Implantation of the blastocyst in the uterine cervix in the region of the internal os may cover the entrance to the cervix, resulting in a condition known as *placenta previa*, in which the placenta may completely or partially cover the internal opening of the cervical canal. Serious hemorrhage may occur as a result of premature separation of the placenta during pregnancy or at delivery.



16.

_____ Ovarian pregnancy

- a. A
- b. B
- c. C
- d. D
- e. E

ANS: D

Ovarian pregnancy is relatively uncommon, with an incidence of approximately 0.5% of all ectopic pregnancies. In an ovarian pregnancy, fertilization of the oocyte probably occurs in the ampulla of the uterine tube with subsequent implantation in the ovary after becoming dislodged from the tube. Because of intra-abdominal hemorrhage and other medical complications, surgical management is necessary.